

Cytological prediction of thyroid cancer aggression as a new promising direction in clinical thyroidology

H.V. Zelinska

State Institution «V.P. Komisarenko Institute of Endocrinology and Metabolism of the NAMS of Ukraine»

Abstract. Despite the favorable prognosis for most patients with papillary thyroid cancer (PTC) there are problems of timely prediction of aggressive subtypes, metastasis, radioiodine resistance (RIR) of PTC, differentiation of indolent from aggressive forms of microcarcinomas, since the treatment tactics depend on this. This report considers a new direction in the development of clinical thyroidology – cytological prediction of aggression and RIR of PTC. **The aim** was to analyze the literature data and present the results of our own studies on the determination of cytological manifestations of aggression and RIR of PTC, which will allow us to develop effective methods for early preoperative prediction of tumor aggression, which will help determine adequate treatment tactics. **Material and methods.** A review of literature sources was conducted, and the data of our own studies were analyzed. Methods of cytological and immunocytochemical examinations of PTC and their metastases smears obtained as a result of fine-needle aspiration biopsy (FNAB) were used. **Results.** Literature data indicate that the latest approach in thyroidology is the determination of certain cytological features (adhesive properties of cells, architecture of cell layers, nuclear-cytoplasmic ratio, presence of atypical histiocytoid cells, multinucleated cells of the foreign body type) as prognostic factors. We have conducted for the first time a comprehensive cytological and immunocytochemical studies of PTC and their metastases punctates of patients with the development of aggression and RIR compared to patients with a positive effect of radioiodine therapy (RIT). This allowed us to propose a decrease in the expression of thyroid peroxidase (TPO), high expression of cytokeratin 17 (CK17) and the emergence of special cellular phenotypes as cytological markers for predicting aggression and RIR of PTC. **Conclusions.** The results of the analysis of literary data and our own studies demonstrate fundamentally new possibilities for using the method of cytological examination of the FNAB material for PTC.

Keywords: papillary thyroid carcinoma, aggression, metastasis, radioiodine-resistant metastases, cytological prediction

PTC is the most common subtype of thyroid cancer, accounting for 80-85% of all thyroid cancers. Patients with differentiated thyroid cancer have a favorable prognosis, with the majority (>95%) surviving for more than 20 years thanks

to an effective treatment protocol based on thyroidectomy followed by RIT [1]. However, some subtypes of PTC exhibit aggressive behavior and poor prognosis. Regional metastases to the cervical lymph nodes occur in 30–50% of patients with

Огляди

PTC, leading to regional tumor recurrence and mortality. The recurrence rate in PTC patients is as high as 25%, according to long-term follow-up statistics [2, 3]. The vast majority of patients with recurrence require surgical reoperations, which is costly and a cause of physical loading for the patient. In addition, reoperation increases the risk of postoperative complications, such as damage to the recurrent laryngeal nerve and temporary or permanent hypoparathyroidism [4]. Therefore, identifying factors that predict lymph node metastasis (LNMs) and recurrence of PCT can significantly help in the diagnosis, treatment, and postoperative monitoring of patients. Preoperative detection of LNMs is crucial for planning PCT surgery. Currently, ultrasound is the best method for screening thyroid and cervical lymph nodes [5]. However, only 20-40% of patients with cervical lymph node metastases can be diagnosed preoperatively by ultrasound [6]. Previous studies have shown that cervical lymph node metastases correlate with histopathological features of PCT, such as lymphatic invasion, the presence of psammomatous bodies, micropapillary structures, discohesive tumor cells, Hobnail and tall cells [7, 8]. However, these histopathological features can be identified in surgical specimens after surgery. A small proportion of PCT shows aggressive clinical behavior, such as high rates of extracapsular invasion (ECI), multifocality, regional and distant metastases, and recurrences [9]. Some aggressive types of PCT are recognized by the World Health Organization as biologically aggressive variants, which include tall-cell, columnar-cell, solid, Hobnail, diffuse-sclerosing, even some non-aggressive subtypes (classical or follicular subtype) can also exhibit aggressive clinical behavior [10]. A serious problem is the presence of aggressive variants among thyroid microcarcinomas, which are important to differentiate from indolent papillary microcarcinomas to determine the tactics of therapy. Therefore, the issue for early prediction of aggressive PTC behavior in order to determine adequate therapy is extremely relevant.

Currently, there are different staging systems for PTC, based on which their behavior is predicted. According to the AMES (age, metastases, extension, size) system, the main prognostic factors are the patient's age, the presence of distant metastases at the time of observation, extrathyroidal extension, and tumor size. According to this system, patients under 40 (men) or 50 (women) years of

age with no distant metastases and patients of any age with carcinoma <5 cm, without extrathyroidal extension and microinvasive follicular histology are classified as a low-risk group, and other patients as a high-risk group. Relapse-free survival rate in patients in the low-risk group is 98.2%, and the recurrence rate is 5.0%, while for high-risk groups these figures are 54.0% and 55.0%, respectively [11]. Another staging system, AGES (age, grade, extension, size), is based on such parameters as age, tumor extension, its size, and histological class. For the low-risk group, 25-year survival is 87%, for the high risk group – 35%. The MACIS (metastases, age, completeness of resection, invasion, size) system takes into account the presence of distant metastases, the patient's age, tumor size, and extrathyroidal extension [12]. In 2009, the American Thyroid Association proposed the TNM (tumor, node, metastases) prognostic system, which classifies patients into very low-risk groups (unifocal, intrathyroid $T_{1a}N_0M_0$), intermediate ($T_{1b}N_0M_0$, $T_2N_0M_0$, or multifocal $T_1N_0M_0$) and the high risk ones (T_3 or T_4N_1 or M_1). The high risk group based on the extrathyroidal tumor extension is divided into intermediate-risk (minimal extrathyroidal extension, N1) and high-risk (massive extrathyroidal extension, M1, incomplete tumor resection) subgroups [13]. Identification of prognostic factors and formation of risk groups of differentiated thyroid cancers helps to formulate individual rational therapeutic approaches that allow avoiding costly unnecessary treatment, but adding really necessary stages. In addition, molecular markers are used for preoperative prediction of differentiated thyroid cancer behavior, on the basis of which risk groups are formed and more or less aggressive surgical tactics are used.

The most important histological factors for tumor behavior are extrathyroidal extension, vascular invasion, tumor size and its multicentric growth. Extrathyroidal extension is considered an independent unfavorable factor for tumor behavior and patient survival. Patients with minor tumor extension (T_3) have a better prognosis compared to those with significant extension (T_4) into the trachea, larynx, and esophagus. For patients with extrathyroidal extension of PTC, the risk of relapse and death is higher than for patients without such extension [14, 15]. Detailed studies have demonstrated an association of extrathyroidal tumor extension with factors that coordinate the regulation of genes involved in the organization of the extra-

cellular matrix, with genes important for iodine transport (SLC5A5 and SLC26A4) [16, 17]. Vascular invasion is considered an important predictor of the distant metastasis development and the effectiveness of RIT for Hurtle cell, follicular, and poorly differentiated thyroid cancers [18]. Tumor size is also the most important prognostic factor for the TC behavior. Its increase correlates with an increase in the frequency of local relapses and negatively affects the patient survival. The presence of distant metastases is also considered an independent prognostic factor. In addition, it is noted that patients with multicentric papillary carcinomas have an older age, a higher TNM stage, and a higher relapse rate than patients with unifocal PTC. Patients with multicentric papillary microcarcinoma demonstrate a higher relapse rate and mortality than patients with unifocal microcarcinoma [18, 19]. The prognostic value of histological classification of tumors was compared with a combined assessment of key histological features, such as severe nuclear atypia, vascular invasion, i.e. with histological class. It turned out that the subclassification of PTC does not have a high prognostic value, while histological class is an important independent marker. The presence of tumor necrosis in histological samples reflects not only tumor biology, but also provides additional valuable information regarding the prognosis. The prognostic value increases if both the subclassification and histological class of the tumor are taken into account. There is evidence that the prognostic value of subclassifications may be low in cases of heterogeneous structure of carcinomas. Other authors believe that the amount of aggressive component of thyroid cancer (insular or poorly differentiated) is important for the prognosis [20, 21]. Thus, there are different staging PTC systems (AMES, AGES, MACIS, TNM), based on which the prognosis of the disease course is carried out, which are based on general clinical characteristics of patients and histological characteristics of tumors. In this case, the prognosis of tumor behavior is carried out at the postoperative stage, when it is impossible to change the approach to surgical intervention.

Since surgical treatment of PTC is currently reduced to a minimum, individual preoperative assessment of thyroid carcinoma aggression is an important component in determining the extent of surgical resection. Due to prophylactic lymphadenectomy, even lymph nodes that do not have me-

tastases are often resected. As a result, the operation volume is unjustifiably increased and problems such as hypocalcemia and recurrent laryngeal nerve damage arise; therefore, debates on the effectiveness and necessity of prophylactic lymphadenectomy continue [4]. While prophylactic removal of central clinically negative (cN0) lymph nodes in PTC was recommended in the previous 2016 American Thyroid Association guidelines, it is no longer recommended in the revised 2009 and 2015 American Thyroid Association guidelines [1, 22].

Therefore, if the required surgical volume could be determined by predicting the LNMs before surgery, it would be possible to select the optimal surgical method for each patient in more detail and reduce various side effects associated with prophylactic lymphadenectomy. It is very important to differentiate aggressive from indolent PTCs at the preoperative stage, which will allow developing an appropriate treatment plan, that include more aggressive surgery, adjuvant therapy and closer surveillance. Intraoperative diagnostics cannot help to determine the exact subtype of PTC and has a high rate of false-negative results of LNMs [23, 24]. At the same time, cytological diagnostics of FNAB material has become widespread and is used as the most effective tool for early preoperative diagnostics of benign and malignant tumors [1, 25, 26]. Previously, the main tasks of cytological diagnostics were differential diagnostics of benign and malignant neoplasms, diagnostics of lymphoproliferative and metastatic processes. Currently, there are much more modern possibilities of cytological diagnostics, in particular, preoperative prediction of tumor behavior, on the basis of which adequate therapy is developed for each specific tumor. The capabilities of the cytological method are significantly increased by the use of immunocytochemical research. There are many examples of successful preoperative prediction of tumor behavior for the selection of adequate therapy using material obtained by FNAB of malignant neoplasms of various localizations (determination of the hormonal status of breast tumors, differential diagnostics of lymphomas etc.) [27]. Fundamentally new possibilities for the use of pancreatic cancer smears material for testing targeted anticancer drugs in culture are shown. Similar approaches are also being developed for anaplastic thyroid cancer [29]. The latest approach in thyroidology is the analysis of certain cytological features of epithelial cells (structure of

Огляди

nuclei and cytoplasm, adhesive properties of cells, cellularity of the smears, architecture of cell sheets, nuclear-cytoplasmic ratio), as well as background cytological processes (the presence of histiocytes, macrophages, multinucleated foreign body cells, the presence of lymphoid infiltration) as prognostic factors of thyroid tumor aggression [30]. Many studies have been conducted on the prognostic LNM factors, since it is their presence that affects the volume of surgical intervention [31, 32]. Y. Zhu et al. using univariate and multivariate analysis using logistic regression identified important cytomorphological features that correlate with some clinicopathological indicators in patients with PTC. The results obtained after analyzing studies conducted in 216 patients showed that cellularity, intranuclear pseudoinclusions, cell adhesion, nuclear size and nuclear pleomorphism were strong predictors of some clinicopathological parameters such as ECI and the LNM presence, while lymphocytes, membrane nuclear regularity and multinucleated giant cells were not prognostic factors [30].

It is known that the adhesive properties of epithelial cells differ in benign and malignant tumors. If in benign tumors the epithelial cells are closely connected to each other, then in malignant tumors the cells lose this adhesive connection, which allows them to separate more easily from the epithelial layer and be ready for migration and metastasis. Cytological assessment of the cell adhesion (degree of aggregation) and the amount of cytoplasm in the cell smears is carried out using a scoring system from 0 to 2. Adhesion score 0 means the presence of predominantly small epithelial layers in the smears and the absence of individual isolated cells. Adhesion score 1 is assigned to smears containing several isolated cells or small epithelial layers. Adhesion score 2 (in this case the adhesive properties of the cells are lost) is assigned to preparations with the presence of predominantly isolated epithelial cells, or the presence of solid cell clusters. Multivariate logistic regression analysis demonstrated that ECI was present in a greater number of patients with a cell adhesion score of 2 than in those with an adhesion score of 0 ($P=0.002$, $OR=5.248$), but there was no significant difference between patients with an adhesion score of 1 and 0. This meant that for PTC, including microcarcinomas, the ECI possibility increases significantly in the presence of predominantly isolated thyrocytes, i.e., epithelial cells with loss of adhesive properties. These studies made it

possible to propose prognostic models of LNM using cytological characteristics in PTC smears. The LNM rates in patients with scores of 2, 1, and 0 were 62.7% (52/83), 31.3% (21/67), and 3.9% (3/76), respectively, i.e., with a gradual decrease in cellular adhesion of PTC, the incidence of LNM increases accordingly. This is of great practical importance in clinical work for making clinical decisions, for example, regarding the need for prophylactic lymph node dissection. The next cytological characteristic that the researchers focused on was the amount of cytoplasm in thyrocytes: scanty (score 0), medium (score 1), and abundant (score 2). The LNM rates of patients with scanty, medium and abundant cytoplasm were 16.7% (15/90), 32.2% (19/59) and 54.5% (42/77), respectively. This may be typical for some aggressive subtypes of PTC with frequent metastasis to the lymph nodes, such as diffuse sclerosing, tall cell, and columnar cell subtypes, the cells of which are characterized by a large amount of cytoplasm. That is, a large amount of cytoplasm in epithelial cells may indicate increased invasiveness of tumors. Thus, such cytomorphological features as cell adhesion and the amount of cytoplasm may be a valuable tool for identifying ECI or LNM in patients with PTC, including the T1 variant (microcarcinomas).

The next promising cytologic factors for predicting thyroid carcinoma behavior were atypical histiocytoid cells and multinucleated giant cells [33]. AHCs detected in FNA material of thyroid and LNM tumors are tumor cells that have a histiocytoid or epithelioid appearance, dark to vesicular nuclei, and abundant cytoplasm [34, 35]. M. Canepa et al. reported that AHCs were identified in 68% FNA of PTC involving cervical lymph node metastases [34]. In their study, AHCs were identified in 122 (55.0%) of 222 aspirates in primary PTC and found a significant correlation between their presence in PTC and LNM smears after surgical resection. Thus, it was suggested that AHCs in FNA of primary PTC do not simply represent cystic variants of PTC, but serve as potential biomarkers for predicting LNM. Studies have shown that BGCs are associated with larger tumor size and extrathyroidal extension of PTC [36]. As a result of the studies conducted, it was shown that cytomorphological characteristics such as AGCs and BGCs observed in FNA material of PTC were significantly correlated with LNM ($p<0.001$ and $p<0.001$, respectively). In multivariate logistic re-

gression analysis, AGCs (OR, 2.761; $p=0.005$) were a significant factor associated with LNM [33]. We have contributed to preoperative tumor prognosis by developing new effective methods for preoperative prognosis of PTC behavior for the first time. The problem of diagnosis and treatment of PTC is RI-resistant metastases (RIRM), the cells of which lose the ability to accumulate RI, which occur in 2-25% of cases. At the same time, the average median survival of patients with distant RIRM is only 2.5–3.5 years [37, 38]. Delay in detection of metastases significantly worsens survival rates of patients with thyroid cancer, so it is important to have the ability to predict the RIRM development early for possible prevention of their appearance or for timely detection. The earliest way to predict RIRM of PTC is preoperative cytological prediction using FNA material. In world practice, molecular genetic methods, such as detection of BRAF gene mutations, are used to predict the thyroid carcinoma behavior on preoperative material. However, these methods are very expensive and can hardly be used in current practice in Ukraine [39]. The basis for the development of RI process in PTC resistance is the disruption of molecular, biological, physical and genetic mechanisms of RI accumulation by thyroid cells [40, 41]. To date, few studies have been conducted to study the molecular, histological and immunohistochemical characteristics of PTC [42, 43]. At the same time, no data on the study of the FNA material and cytological characteristics that could correlate with the iodine-accumulating capacity of PTC were found in the scientific literature. The analysis of the scientific literature on this issue prompted us to conduct a pilot complex cytological and immunocytochemical study of the PTC smears material (in comparison with the corresponding groups of PTC and their metastases) in order to identify characteristic cytological features and create, on their basis, methods for preoperative predicting RIR.

We have conducted a comprehensive cytological and immunocytochemical study of FNA smears from 161 RIRM of PTCs compared with 164 patients with a positive effect of RIT and 90 primary PTCs. This allowed us to detect some specific cytological and immunocytochemical features of their thyrocytes and, on this basis, to develop for the first time methods for preoperative prediction of aggression and RIR in PTCs. We propose the use of decreased TPO expression, high expression of CK17,

and the emergence of special cellular phenotypes as cytological markers for predicting aggression and RIR in PTCs. The analysis of the correlation between a number of epithelial cells reacting with antibodies to TPO in the FNA smears samples of PTC and the frequency of metastases detection in these patients in the postoperative period (after thyroidectomy and RIT) proves the presence of an inverse correlation between the parameters ($p<0.05$), both by the definition of gamma correlation (-0.489362) and by the Spearman method (-0.344788). It was shown that with a high content of thyrocytes and a positive reaction of antibodies to TPO (TPO+) in smears of the primary PTC (from 50 to 92%), metastases were not detected in the postoperative period. At the same time, the appearance of RIRM was recorded only in cases of the absence of TPO expression in the FNA smears material of PTC, or if it occurred in a maximum of 25.0% of thyrocytes in the smears. The results of the conducted studies show that the determination of the thyrocytes content with the TPO presence in the FNAB material of PTC can be used to predict their behavior and metastasis tendencies in the postoperative period. The absence of expression or a low percentage (less than 25%) of thyrocytes with TPO in the material of PTC FNA smears does not exclude metastasis in the postoperative period and the occurrence of RIRM, a high percentage of TPO+ epithelial cells in the smears (more than 50%) allows predicting a favorable tumor behavior without waiting for the formation of postoperative metastases [44]. The use of immunocytochemical detection of cells containing cytokeratin No. 17 (CK17) in PTC FNA smears allows predicting the occurrence of RIRM with 70% significance in cases where the percentage of these cells is more than 10% [45]. This method allows identifying a risk group of patients with a high significance of RIRM and more carefully monitoring them. That is, in the presence of RI-negative scanograms, use additional research methods (X-ray, ultrasound, FDG PET diagnostics). Given the high risk of aggression of CK17-positive PTC, hemithyroidectomy should be avoided even in cases of small size of such carcinomas.

We have demonstrated the presence of phenotypic heterogeneity of follicular epithelium in the RIRM FNA smears of PTC, which was manifested by a greater diversity of subclones and structures of thyrocytes compared to RI-sensitive metastases (RISM). One of the cytological features of RISM

Огляди

is the presence of special phenotypes of epitheliocytes (S- or «light» cells), which differed from the general population of epithelium by the presence of a clear contour, light cytoplasm, and the absence of thyroglobulin and TPO involved in the RI accumulation. The difference between the frequency of metastasis in the groups with and without S-cells in the FNA smears of primary PTCs was statistically confirmed ($p = 0.0272$). It was shown that postoperative metastases, including RIRMs, were identified in 60.97% cases of the S-cell presence in smears of primary PTCs. At the same time, in patients with the absence of these cells in the PTC smears, such metastases were determined only in 35.42%. The study of the correlation between the S-cell presence in the smears of primary PCT and the number of regional metastases showed that in patients with multiple regional metastases, these cells were detected in 42% of cases, while in patients with the absence of regional metastases, S-cells were detected only in 22% of cases ($p < 0.05$) [44]. **Figure 1** shows the scheme for predicting postoperative metastases based on the detection of cytological factors in the FNA material of PTC.

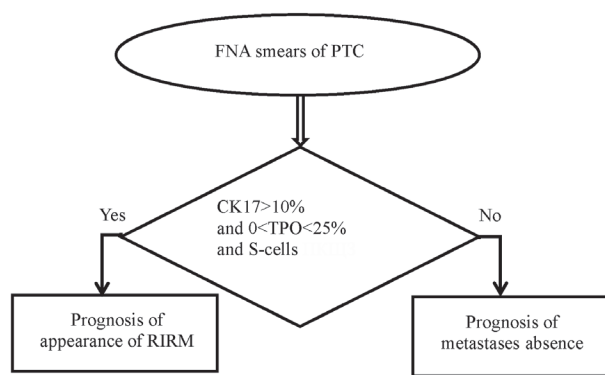


Fig. 1. Algorithm for predicting the appearance of metastases in the postoperative period based on the identification of cytological factors in the material of PTC FNAB.

The next method of preoperative prediction of PTC RIRM concerns metastases that can appear in the postoperative period even against the background of standard treatment of thyroid cancer (thyroidectomy, hormonal suppressive therapy, RI therapy). It is known that the conditions for effective accumulation of RI by thyrocytes are not only its absorption by the cell, but also the effective period of isotope half-life. The period of iodine organization, which is catalyzed by TPO, has an important

influence on it. A decrease in the process of iodine organization due to a decrease in TPO expression leads to its rapid efflux from the cell and reduces the efficiency of RI accumulation [46]. A significant difference was determined between the percentage of TPO+ thyrocytes in RIRM and RISM of PTC ($p < 0.001$). Statistical analysis showed that the median specific gravity of cells containing TPO for the RIRM group was 0, and for the RISM group – 72.5%. We will use the median of 72.5% as the average percentage of TPO+ cells, the excess of which clearly indicates RI sensitivity of the metastasis. At the same time, the absence of cells with TPO clearly indicates RIR of the metastasis. The maximum percentage of TPO+ cells was 20% for the RIRM group, which is lower than the minimum value of the same indicator for the RISM group (30%).

Analysis of the effectiveness for the conducted RIT demonstrated that, despite the fact that all metastases in this group accumulated RI, the RIT effectiveness of patients with different percentages of TPO+ cells was different. Thus, in 75.0% of cases, RIT was successful in patients of this group. In such patients, the percentage of TPO+ cells in the punctates (aspirates) of postoperative metastases exceeded 60%. At the same time, in 25% of patients of this group, although metastases initially accumulated RI, they lost this ability over time, i.e. secondary RIR of metastases developed. The latter were removed surgically. The relative number of TPO+ cells in the FNA smears of these metastases ranged from 30 to 50%. This indicates that intermediate values of the specific gravity of TPO+ cells (from 30 to 50%), although they suggest moderate RI accumulation, but it may be insufficient for successful RIT. These results allowed us to propose for the first time a new method for preoperative prediction of RIR and determination of the RIT efficiency for PTC based on immunocytochemical determination of TPO expression in the FNA smears of postoperative metastases. The absence of TPO expression indicates the inability of metastatic cells to accumulate RI, the futility of treating this metastasis with RI and the advisability of its surgical removal. If more than 72.5% of the thyrocytes of the metastasis smears contain TPO, the ability of the metastasis to accumulate RI, high efficiency and the appropriateness of further RIT are assumed. If the content of TPO+ cells in the metastasis smears is from 30% to 50%, moderate accumulation of RI is possible, but the efficiency of RIT may be low [47].

Literature data confirm that TPO can be a prognostic factor for thyroid tumor aggression. Immunohistochemical determination of this antigen in the material of thyroid neoplasms is considered as a factor for metastasis and recurrence [48]. A strong negative correlation was demonstrated between TPO expression in the histological material of PTC and metastasis to the lymph nodes in patients ($p=0.004$). The results of the studies showed that TPO expression at the TNMIV tumor stage significantly exceeded that ($p<0.0001$), and the level of TPO expression was significantly lower at tumor stages T3 and T4 than at stage T1. In addition, TPO expression was significantly higher in patients with PTC without LNMs than in patients with such metastasis ($p<0.0001$), confirming the role of TPO expression in predicting LNM [48].

Our cytological studies of RIRM and RISM smears demonstrated that RIRM are characterized by phenotypic heterogeneity of the epithelium, represented by special cellular phenotypes, such as «clear cells», the presence of cystic degeneration and special cellular complexes (psamomal bodies surrounded by thyrocytes with signs of vacuolation). Correlation analysis of the presence of the cytological sign of cystic degeneration and TPO expression in RIRM of PTC smears did not reveal a relationship between these factors of preoperative prognosis of RIR (Spearman's rank correlation coefficient is -0.061967). That is, the presence of cystic degeneration and TPO expression in postoperative metastases act as independent cytological prognostic factors of RIR of PTC [44]. The scheme for cytological prognosis of RIRM is presented in Fig. 2.

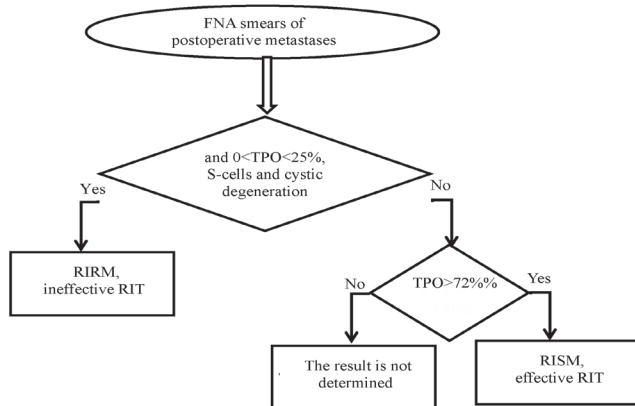


Fig. 2. Algorithm for predicting RIR of metastases based on the detection of cytological factors in their FNA smears.

Thus, this work shows fundamentally new possibilities for using the method of cytological examination of FNA material for PTC.

References

- Haugen BR, Alexander EK, Bible KC, Doherty GM, Mandel SJ, Nikiforov YE, et al. 2015 American Thyroid Association management guidelines for adult patients with thyroid nodules and differentiated thyroid cancer: the American Thyroid Association guidelines task force on thyroid nodules and differentiated thyroid cancer. *Thyroid*. 2016 Jan;26(1):1-133. doi: 10.1089/thy.2015.0020.
- Pyo JS, Sohn JH, Chang K. Prognostic role of metastatic lymph node ratio in papillary thyroid carcinoma. *J Pathol Transl Med*. 2018 Sep;52(5):331-8. doi: 10.4132/jptm.2018.08.07.
- Liu FH, Kuo SF, Hsueh C, Chao TC, Lin JD. Postoperative recurrence of papillary thyroid carcinoma with lymph node metastasis. *J Surg Oncol*. 2015 Aug;112(2):149-54. doi: 10.1002/jso.23967.
- Sitges-Serra A, Lorente L, Mateu G, Sancho JJ. Therapy of endocrine disease: Central neck dissection: a step forward in the treatment of papillary thyroid cancer. *Eur J Endocrinol*. 2015 Dec;173(6):R199-206. doi: 10.1530/EJE-15-0481.
- Zhao H, Li H. Meta-analysis of ultrasound for cervical lymph nodes in papillary thyroid cancer: Diagnosis of central and lateral compartment nodal metastases. *Eur J Radiol*. 2019 Mar;112:14-21. doi: 10.1016/j.ejrad.2019.01.006.
- Lee YJ, Kim DW, Park HK, Kim DH, Jung SJ, Oh M, et al. Pre-operative ultrasound diagnosis of nodal metastasis in papillary thyroid carcinoma patients according to nodal compartment. *Ultrasound Med Biol*. 2015 May;41(5):1294-300. doi: 10.1016/j.ultrasmedbio.2015.01.003.
- Cai YF, Wang QX, Ni CJ, Guo GL, Li Q, Wang OC, et al. The clinical relevance of psammoma body and Hashimoto thyroiditis in papillary thyroid carcinoma: a large case-control study. *Medicine (Baltimore)*. 2015 Nov;94(44):e1881. doi: 10.1097/MD.0000000000001881.
- Kim Y, Kim MH, Jeon S, Kim J, Kim C, Bae JS, et al. Prognostic implication of histological features associated with EHD2 expression in papillary thyroid carcinoma. *PLoS One*. 2017 Mar 30;12(3):e0174737. doi: 10.1371/journal.pone.0174737.
- Tumors of the thyroid gland. In: Lloyd RV, Osamura RY, Kloppel G, Rosai J, eds. WHO classifications of tumours of the endocrine organs. 4th ed. Geneva, Switzerland: World Health Organization; 2017.
- Roman S, Sosa JA. Aggressive variants of papillary thyroid cancer. *Curr Opin Oncol*. 2013 Jan;25(1):33-8. doi: 10.1097/CCO.0b013e32835b7c6b.
- Cramer JD, Fu P, Harth KC, Margevicius S, Wilhelm SM. Analysis of the rising incidence of thyroid cancer using the surveillance, epidemiology and end results national cancer data registry. *Surgery*. 2010 Dec;148(6):1147-52; discussion 1152-3. doi: 10.1016/j.surg.2010.10.016.
- Teo KW, Yuan NK, Tan WB, Parameswaran R. Comparison of prognostic scoring systems in follicular thyroid cancer. *Ann R Coll Surg Engl*. 2017 Jul;99(6):479-84. doi: 10.1308/rcsann.2017.0072.
- Casella C, Ministrini S, Galani A, Mastriale F, Cappelli C, Portolani N. The new TNM staging system for thyroid cancer and the risk of disease downstaging. *Front Endocrinol (Lausanne)*. 2018 Sep 18;9:541. doi: 10.3389/fendo.2018.00541.
- Anwar SL, Cahyono R, Suwardjo S, Hardiyanto H. Extrathyroidal extension and cervical node infiltration are associated with recurrences and shorter recurrence-free survival in differentiated thyroid cancer: a cohort study. *Thyroid Res*. 2022 Jul 26;15(1):13. doi: 10.1186/s13044-022-00131-7.
- Kauffmann RM, Hamner JB, Ituarte PHG, Yim JH. Age greater than 60 years portends a worse prognosis in patients with papillary thyroid cancer: should there be three age categories for staging? *BMC Cancer*. 2018 Mar 22;18(1):316. doi: 10.1186/s12885-018-4181-4.
- Medas F, Canu GL, Boi F, Lai ML, Erdas E, Calò PG. Predictive factors of recurrence in patients with differentiated thyroid

Огляди

- carcinoma: a retrospective analysis on 579 patients. *Cancers* (Basel). 2019 Aug 22;11(9):1230. doi: 10.3390/cancers11091230.
17. Sun JH, Li YR, Chang KH, Liou MJ, Lin SF, Tsai SS, et al. Evaluation of recurrence risk in patients with papillary thyroid cancer through tumor-node-metastasis staging: A single-center observational study in Taiwan. *Biomed J*. 2022 Dec;45(6):923-930. doi: 10.1016/j.bj.2021.11.009.
 18. Wresmann VB, Nixon IJ, Rivera M, Katabi N, Palmer F, Ganly I, et al. Prognostic value of vascular invasion in well-differentiated papillary thyroid carcinoma. *Thyroid*. 2015 May;25(5):503-8. doi: 10.1089/thy.2015.0052.
 19. Barbosa MP, Momesso D, Bulzico DA, Farias T, Dias F, Lima RA, et al. Metastatic lymph node characteristics as predictors of recurrence/persistence in the neck and distant metastases in differentiated thyroid cancer. *Arch EndocrinolMetab*. 2017 Dec;61(6):584-9. doi: 10.1590/2359-399700000307.
 20. Akslen LA, LiVolsi VA. Prognostic significance of histologic grading compared with subclassification of papillary thyroid carcinoma. *Cancer*. 2000 Apr 15;88(8):1902-8.
 21. Wassermann J, Bernier MO, Spano JP, Lepoutre-Lussey C, Buffet C, Simon JM, et al. Outcomes and prognostic factors in radioiodine refractory differentiated thyroid carcinomas. *Oncologist*. 2016 Jan;21(1):50-8. doi: 10.1634/theoncologist.2015-0107.
 22. Cooper DS, Doherty GM, Haugen BR, Kloos RT, Lee SL, Mandel SJ, et al. Management guidelines for patients with thyroid nodules and differentiated thyroid cancer. *Thyroid*. 2006 Feb;16(2):109-42. doi: 10.1089/thy.2006.16.109.
 23. Jozaghi Y, Richardson K, Anand S, Mlynarek A, Hier MP, Forest VI, et al. Frozen section analysis and sentinel lymph node biopsy in well differentiated thyroid cancer. *J Otolaryngol Head Neck Surg*. 2013 Sep 11;42(1):48. doi: 10.1186/1916-0216-42-48.
 24. Ji YB, Lee DW, Song CM, Kim KR, Park CW, Tae K. Accuracy of intraoperative determination of central node metastasis by the surgeon in papillary thyroid carcinoma. *Otolaryngol Head Neck Surg*. 2014 Apr;150(4):542-7. doi: 10.1177/0194599813519405.
 25. Zhu Y, Song Y, Xu G, Fan Z, Ren W. The Bethesda System for Reporting Thyroid Cytopathology (TBSRTC): A report of 2,781 cases in a Chinese population. *Chin J Cancer Res*. 2020 Apr;32(2):140-8. doi: 10.21147/j.issn.1000-9604.2020.02.02.
 26. Pusztaszeri MP, Auger M, Stelow EB, Yang GC, Sanchez MA, LiVolsi VA. Papillary thyroid carcinoma, variants, and related tumors. In *The Bethesda System for Reporting Thyroid Cytopathology: definitions, criteria, and explanatory notes*; Ali SZ, Cibas ES, eds.; Springer International Publishing: Cham, Switzerland; 2018. p. 119-56.
 27. Marrazzo A, Taormina P, Leonardi P, Lupo F, Filosto S. Immunocytochemical determination of estrogen and progesterone receptors on 219 fine-needle aspirates of breast cancer. A prospective study. *Anticancer Res*. 1995 Mar-Apr;15(2):521-6.
 28. Cho J. Basic immunohistochemistry for lymphoma diagnosis. *Blood Res*. 2022 Apr 30;57(S1):55-61. doi: 10.5045/br.2022.2022037.
 29. Eckhardt S, Hoffmann S, Damanakis AI, Di Fazio P, Pfestroff A, Luster M, et al. Individualized multimodal treatment strategy for anaplastic thyroid carcinoma – Case report of long-term remission and review of literature. *Int J Surg Case Rep*. 2016;25:174-8. doi: 10.1016/j.ijscr.2016.06.013.
 30. Zhu Y, Ren W, Song Y, Fan Z, Wang Q, Jin H, et al. Cytomorphologic features as predictors of aggressiveness in patients with pT1 papillary thyroid carcinoma: a retrospective study of associations with clinicopathological parameters in 226 fine-needle aspirates. *Gland Surg*. 2021 Jan;10(1):319-327. doi: 10.21037/gs-20-618.
 31. Legesse T, Parker L, Heath J, Staats PN. Distinguishing non-invasive follicular thyroid neoplasm with papillary-like nuclear features (NIFTP) from classic and invasive follicular-variant papillary thyroid carcinomas based on cytologic features. *J Am Soc Cytopathol*. 2019 Jan-Feb;8(1):11-7. doi: 10.1016/j.jasc.2018.07.004.
 32. Rossi ED, Faquin WC, Pantanowitz L. Cytologic features of aggressive variants of follicular-derived thyroid carcinoma. *Cancer Cytopathol*. 2019 Jul;127(7):432-46. doi: 10.1002/ency.22136.
 33. Choi JE, Bae JS, Lim DJ, Jung SL, Jung CK. Atypical histiocytoid cells and multinucleated giant cells in fine-needle aspiration cytology of the thyroid predict lymph node metastasis of papillary thyroid carcinoma. *Cancers* (Basel). 2019 Jun 12;11(6):816. doi: 10.3390/cancers11060816.
 34. Canepa M, Elsheikh TM, Sabo DA, Kolosiwsky AM, Reynolds JP. Atypical histiocytoid cells in metastatic papillary thyroid carcinoma: an underrecognized cytologic pattern. *Am J Clin Pathol*. 2017 Jul 1;148(1):58-63. doi: 10.1093/ajcp/aqx049.
 35. Chen YA, Lin SJ, Teng HY, Yang CS. Atypical histiocytoid cells in fine-needle aspiration cytology of metastatic papillary thyroid carcinoma: a potential diagnostic pitfall. *Diagn Cytopathol*. 2022 Mar;50(3):133-40. doi: 10.1002/dc.24932.
 36. Brooks E, Simmons-Arnold L, Naud S, Evans MF, Elhosseiny A. Multinucleated giant cells' incidence, immune markers, and significance: a study of 172 cases of papillary thyroid carcinoma. *Head Neck Pathol*. 2009 Jun;3(2):95-9. doi: 10.1007/s12105-009-0110-9.
 37. Shen H, Zhu R, Liu Y, Hong Y, Ge J, Xuan J, et al. Radioiodine-refractory differentiated thyroid cancer: Molecular mechanisms and therapeutic strategies for radioiodine resistance. *Drug Resist Updat*. 2024 Jan;72:101013. doi: 10.1016/j.drug.2023.101013.
 38. Petranović Oščariček P, de Keizer B, Campenni A, Kreissl MC, Deandrei D, et al. Radioiodine-refractory thyroid cancer-is it time to change the definition in light of novel redifferentiation therapies? *Eur J Nucl Med Mol Imaging*. 2024 Nov 19. doi: 10.1007/s00259-024-06991-5.
 39. Colombo C, Minna E, Gargiuli C, Muzza M, Dugo M, De Cecco L, et al. The molecular and gene/miRNA expression profiles of radioiodine resistant papillary thyroid cancer. *J Exp Clin Cancer Res*. 2020 Nov 16;39(1):245. doi: 10.1186/s13046-020-01757-x.
 40. Oh JM, Ahn BC. Molecular mechanisms of radioactive iodine refractoriness in differentiated thyroid cancer: impaired sodium iodide symporter (NIS) expression owing to altered signaling pathway activity and intracellular localization of NIS. *Theranostics*. 2021 Apr 15;11(13):6251-77. doi: 10.7150/thno.57689.
 41. Chai J, Zhang R, Zheng W, Zhang G, Jia Q, Tan J, et al. Predictive value of clinical and pathological characteristics for metastatic radioactive iodine-refractory differentiated thyroid carcinoma: a 16-year retrospective study. *Front Endocrinol (Lausanne)*. 2022 Jun 28;13:930180. doi: 10.3389/fendo.2022.930180.
 42. Stegenga MT, van Velsen EFS, Oudijk L, Verburg FA, van Ginhoven TM, Peeters RP, et al. Clinical and histopathological risk factors for radioactive iodine-refractory follicular and oncocytic thyroid carcinoma. *J Clin Endocrinol Metab*. 2024 Nov 18;109(12):e2334-41. doi: 10.1210/clinem/dgae084.
 43. Luo Y, Jiang H, Xu W, Wang X, Ma B, Liao T, et al. Clinical, pathological, and molecular characteristics correlating to the occurrence of radioiodine refractory differentiated thyroid carcinoma: a systematic review and meta-analysis. *Front Oncol*. 2020 Sep 30;10:549882. doi: 10.3389/fonc.2020.549882.
 44. Tronko M, Zelinska H, Bozhok Yu, Kvachenyuk A, Gulevatyi S, Kulnichenko H, et al. Cytological factors in the prognosis of postoperative metastasis and radioiodine resistance in papillary thyroid cancer. *Endokrynologia*. 2021;26(4):326-35. doi: 10.31793/1680-1466.2021.26-4.326.
 45. Zelinska HV. Cytokeratin No. 17 and thyroid peroxidase as immunocytochemical markers for preoperative prediction of radioiodine resistance and efficacy of radioiodine therapy for papillary thyroid cancer. *Oncology*. 2019;21(1):31-5.
 46. Calil-Silveira J, Serrano-Nascimento C, Kopp PA, Nunes MT. Iodide excess regulates its own efflux: a possible involvement of pendrin. *Am J Physiol Cell Physiol*. 2016 Apr 1;310(7):C576-82. doi: 10.1152/ajpcell.00210.2015.
 47. Zelinskaya A. Immunocytochemical characteristics of thyrocytes in radioiodine refractory metastases of papillary thyroid cancer. *Experimental Oncology*. 2019; 41(4): 342–5. doi: 10.32471/exp-oncology.2312-8852.vol-41-no-4.13705.
 48. Li X, Cheng R. TPO as an indicator of lymph node metastasis and recurrence in papillary thyroid carcinoma. *Sci Rep*. 2023 Jul 5;13(1):10848. doi: 10.1038/s41598-023-37932-1.

Abbreviations

ECI – extra capsular invasion

LNM – lymph node metastasis

PTC – papillary thyroid carcinoma

RIT – radioiodine therapy
RI – radioiodine
RIR – radioiodine resistance
RIRM – radioiodine resistant metastasis
RISM – radioiodine sensitive metastases
FNAB – fine-needle aspiration biopsy
TPO – thyroid peroxidase
CK17 – cytokeratin 17

Цитологічне прогнозування агресії раку щитоподібної залози як новітній перспективний напрямок у клінічній тиреоїдології

Г.В. Зелінська

ДУ «Інститут ендокринології та обміну речовин ім. В.П. Комісаренка НАМН України»

Резюме. Незважаючи на сприятливий прогноз для більшості пацієнтів із папілярною карциномою щитоподібної залози (ПКЩЗ), існують проблеми своєчасного прогнозування агресивних субтипів, метастазування, радіюдрезистентності ПКЩЗ, диференціювання індолентних від агресивних форм мікрокарцином, оскільки від цього залежить тактика лікування. У цьому повідомленні розглянутий новий напрямок розвитку клінічної тиреоїдології – цитологічне прогнозування агресії та радіюдрезистентності ПКЩЗ. **Мета.** Проаналізувати літературні дані та навести результати власних досліджень щодо визначення цитологічних проявів агресії та радіюдрезистентності ПКЩЗ, що дозволить розробити ефективні методи раннього передопераційного прогнозування агресії пухлин, що допоможе визначити адекватну тактику лікування. **Матеріал і методи.** Проведено огляд джерел літератури, проаналізовано дані власних досліджень. Використані методи цитологічного та імуноцитохімічного дослідження пунктів ПКЩЗ та їх метастазів, отриманих у результаті проведення тонкогільчастої аспіраційної пункційної біопсії (ТАПБ). **Результати.** Літературні дані свідчать, що новітнім підходом у тиреоїдології є визначення певних цитологічних ознак (адгезивних властивостей клітин, архітектури клітинних пластів, ядерно-цитоплазматичного співвідношення, наявності атипичних гістіоцитоїдних клітин, багатоядерних клітин типу інородних тіл) в якості прогностичних чинників агресії пухлин щитоподібної залози. Нами вперше проведено комплексне цитологічне та імуноцитохімічне дослідження пунктів ПКЩЗ та їх метастазів пацієнтів із розвитком агресії та радіюдрезистентності порівняно з пацієнтами з позитивним ефектом радіюдотерапії. Це дозволило запропонувати зниження експресії тиреоїдної пероксидази (ТПО), високу експресію цитокератину 17 (ЦК17) та появу особливих клітинних

фенотипів в якості цитологічних маркерів прогнозування агресії та радіюдрезистентності ПКЩЗ. **Висновки.** Результати аналізу літературних даних та власних досліджень демонструють принципово нові можливості використання методу цитологічного дослідження матеріалу ТАПБ ПКЩЗ.

Ключові слова: папілярна карцинома щитоподібної залози, агресія, метастазування, радіюдрезистентні метастази, цитологічне прогнозування

For citation: Zelinska HV. Cytological prediction of thyroid cancer aggression as a new promising direction in clinical thyroidology. Endokrynologia. 2024;29(4):363-371. DOI: 10.31793/1680-1466.2024.29-4.363.

Correspondence address: Zelinska Hanna Volodymyrivna, ann.zelinskaya@ukr.net; State Institution «VP Komisarenko Institute of Endocrinology and Metabolism of the NAMS of Ukraine», Vyshgorodska Str., 69, Kyiv 04114, Ukraine.

Information about the author: Zelinska Hanna Volodymyrivna, Dr. Sci. (Biology), Senior Researcher of Functional and Ultrasound Diagnostic Laboratory, ORCID: 0000-0001-7421-0981.

Personal contribution: Zelinska H.V. – concept and design of research, literature analysis, cytological and immunocytochemical researches, analysis and interpretation of the results, writing an article.

Funding: the study was carried out within the budget funding according to the plan of research work of the State Institution «V.P. Komisarenko Institute of Endocrinology and Metabolism of the NAMS of Ukraine» (registration number: 0120U10064).

Declaration of ethics: the author have declared no conflicts of interest or financial obligations.

Article: received November 23, 2024; revised November 26, 2024; accepted November 26, 2024; published December 30, 2024.

Для цитування: Зелінська Г.В. Цитологічне прогнозування агресії раку щитоподібної залози як новий перспективний напрямок у клінічній тиреоїдології. Ендокринологія. 2024;29(4):363-371. DOI: 10.31793/1680-1466.2024.29-4.363.

Адреса для листування: Зелінська Ганна Володимирівна, ann.zelinskaya@ukr.net; ДУ «Інститут ендокринології та обміну речовин ім. В.П. Комісаренка НАМН України», вул. Вишгородська, 69, м. Київ 04114, Україна.

Відомості про автора: Зелінська Ганна Володимирівна, д-рка біол. наук, старша наукова співробітниця лабораторії функціональної та ультразвукової діагностики, ORCID: 0000-0001-7421-0981.

Особистий внесок: Зелінська Г.В. – концепція та дизайн дослідження, аналіз літератури, цитологічні та імуноцитохімічні дослідження, аналіз та інтерпретація результатів, написання статті.

Фінансування: дослідження виконано в межах бюджетного фінансування згідно з планом науково-дослідної роботи ДУ «Інститут ендокринології та обміну речовин ім. В.П. Комісаренка НАМН України» (реєстраційний номер 0120U10064).

Декларація з етики: автор заявив про відсутність конфлікту інтересів або фінансових зобов'язань.

Стаття: надійшла до редакції 23.11.2024 р.; перероблена 26.11.2024 р.; прийнята до друку 26.11.2024 р.; надрукована 30.12.2024 р.